

Synchronous Colitis Induced by Hot Water Enema-An Easily Missed Etiology for Colitis in Modern Days

Hsu TC^{1,2,3*}, Sun WC¹, Chen MJ³, Lin WC⁴ and Wang HY⁴

¹Division of Colon and Rectal Surgery, Department of Surgery, Taipei Mackay Memorial Hospital, Taipei, Taiwan

²Department of Surgery, Taipei Medical University, Taipei, Taiwan

³Department of Surgery, Mackay Medical College, New Taipei, Taiwan

⁴Division of Gastroenterology, Department of Internal Medicine, Mackay Memorial Hospital, Taipei, Taiwan

*Corresponding author:

Tzu-Chi Hsu,
Division of Colon and Rectal Surgery,
Department of Surgery, Taipei Mackay Memorial
Hospital, Taipei, Taiwan, Tel: 011-8862-2543-3535;
Fax: 011-8862-2543-3642,
E-mail: tzuchi@mmh.org.tw

Received: 04 Dec 2020

Accepted: 07 Dec 2020

Published: 21 Dec 2020

Copyright:

©2020 Hsu TC. This is an open access article distributed under the terms of the Creative Commons Attribution License, which permits unrestricted use, distribution, and build upon your work non-commercially.

Citation:

Hsu TC. Synchronous Colitis Induced by Hot Water Enema-An Easily Missed Etiology for Colitis in Modern Days. Japanese Journal of Gastroenterology and Hepatology. 2020; V5(7): 1-5.

Keywords:

Colitis; Enema; Hot water; Practitioner

1. Abstract

1.1. Background: Colitis caused by hot water was not seen frequently in the past, however, in recent times it is increasingly seen in the clinic. Colitis caused by hot water might be associated with complications such as rectal burn, permanent rectal stricture and bowel perforation, and even death [1].

1.2. Aims: Colitis caused by hot water might be misdiagnosed as other type specific or non-specific colitis by general practitioners or even by specialists. It is essential to differentiate colitis caused by hot water with other types of colitis or malignancies.

1.3. Design: February 2016 to August 2017, patients presented with colitis caused by hot water enema in the past one and a half years were analyzed.

Settings: The study last for a one and a half year and was performed in the medical record room and colorectal surgical department. Twelve patients presented with colitis caused by hot water enema from February 2016 to August 2017.

1.4. Patients: There were nine males and three females. Their Ages ranged from 18 to 72 years old, with an average age of 35.9 years old. Three patients reported that they were MSM. Two patients had colectomy for carcinoma of rectum. Two patients were admitted to the hospital due to severe anemia and required blood transfusion. The cause of colitis in these patient with thermal injury might be

due to application of hot water enema for sanitation or application of hot coffee enema as an alternative medicine for treatment of constipation. Twelve patients presented with colitis caused by hot water enema in the past one and a half years. There were nine males and three females. Their Ages ranged from 18 to 72 years old, with an average age of 35.9 years old. Three patients reported that they were MSM. Two patients had colectomy for carcinoma of rectum. Two patients were admitted to the hospital due to severe anemia and required blood transfusion. The cause of colitis in these patient with thermal injury might be due to application of hot water enema for sanitation or application of hot coffee enema as an alternative medicine for treatment of constipation.

1.5. Interventions(s): Endoscopy for diagnosis of colitis.

1.6. Main Outcome Measures: Diagnosis were made from history taking, physical examination, endoscopy finding and pathology report.

1.7. Materials and Methods: Twelve patients presented with colitis caused by hot water enema in the past one and a half years. There were nine males and three females. Their Ages ranged from 18 to 72 years old, with an average age of 35.9 years old. Three patients reported that they were men who have sex with men (MSM). Two patients had colectomy for carcinoma of rectum. The cause of colitis in these patients with thermal injury might be due to application of hot water enema for sanitation or application of hot coffee enema as

an alternative medicine for treatment of constipation.

1.8. Results: Chief complaints of the patients were rectal bleeding, rectal mucous discharge, or tenesmus. Endoscopy findings were non-specific. Pathology reports were also either non-specific inflammation or granulation. At least five patients were seen by a board certified gastroenterologist or colorectal surgeon prior to being seen by authors for correct diagnosis. All of the patients had control of their colitis after stopping hot water enema.

1.9. Limitations: It is a retrospective study and difficult to reflect the true incidence of colitis induced by hot water in the population.

1.10. Conclusion: Scalding injury by hot water is not a commonly seen disease but might increase in modern days due to herbal remedies used by holistic practitioners. Maladjustment and malfunction of electronic bidet might increase chance of scalding injury. Early diagnosis and appropriate management is essential for patient's outcome [2].

2. Introduction

2.1. Scalding Injury by Hot Water is a Commonly Seen Disease

Colitis caused by hot water was not frequently seen in the past, However, recently it is increasingly seen in the clinic. Colitis caused by hot water might be associated with complications such as rectal burn, permanent rectal stricture and bowel perforation, and even death. Colitis caused by hot water might be misdiagnosed as other type specific or non-specific colitis by general practitioners or even by specialists [3].

3. Materials and Methods

This is a retrospective study of colitis caused by hot water enema. Twelve patients presented with colitis caused by hot water enema from February 2016 to August 2017. There were nine males and three females. Their Ages ranged from 18 to 72 years old, with an average age of 35.9 years old. Three patients reported that they were men who have sex with men (MSM). Two patients had colectomy for carcinoma of rectum previously. Two patients were admitted due to severe anemia and required blood transfusion. The cause of colitis in these patients with thermal injury might be due to application of hot water enema for sanitation in nine patients and application of hot coffee enema as an alternative medicine for treatment of constipation in three patients.

4. Results

Chief complaints of the patients were mainly rectal bleeding, rectal mucous discharge, or tenesmus. A few patients also complained about anal pain, dizziness, or fatigue. Initially, none of the patients reported that he or she used hot water enema. Endoscopy findings were mucosal congestion, edema, and easy contact bleeding, together with ulceration or necrosis; none of those findings were specific. Pathology reports were also either non-specific inflammation or granulation. At least five patients were seen by a board certified gas-

troenterologist or colorectal surgeon, had endoscopic examinations, and even biopsies prior to being seen by the authors for correct diagnosis. All of the patients had control of their colitis after stopping hot water enema [4].

4.1. Illustration of Five Cases for Detailed Description of Their History, Examination, and Management

4.2. Case 1

An 18-year-old male, admitted to the hospital with chief complaint of rectal bleeding for a few days. Severe anemia with hemoglobin 4.9 g/dL (normal range of 13-18 g/dL) was found. Colonoscopy performed by a gastroenterologist revealed several wide-based polypoid lesions in the rectum with satellite lesions (Figure 1). Pathology report of biopsy was granulation tissue with chronic active inflammation. A consultation to a colorectal surgeon was called. Colonoscopy with polypectomy a week later by the surgeon revealed erythematous fibrous mucosa and a rectal polyp with easy contact bleeding. Pathology of rectal biopsy revealed granulation tissue. Patient reported that he frequently used hot water to clean the rectum for constipation and sanitary purpose.

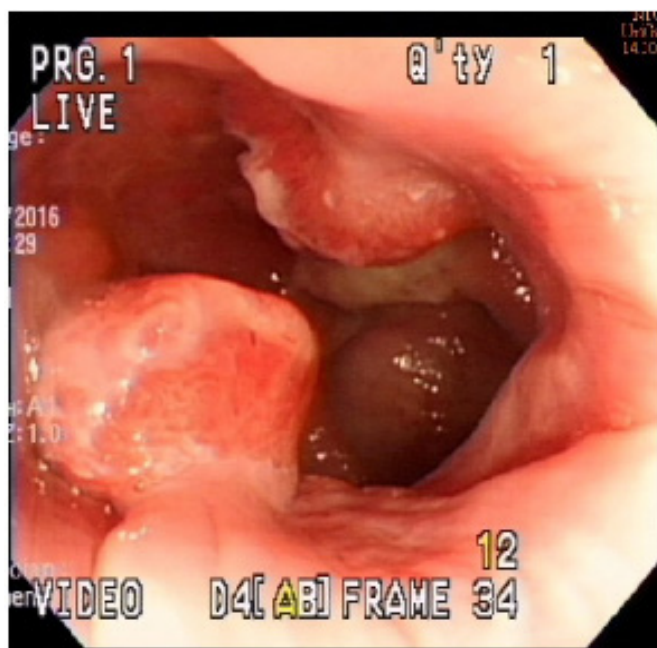

Figure 1: Colonoscopy revealed several wide based polypoid lesions in the rectum with satellite lesions.

4.3. Case 2

A 27-year-old male presented with anal bleeding following bowel movement for a few days. He reported that he is a man who has sex with men (MSM). Flexible sigmoidoscopy revealed friable edematous mucosa of rectum with multiple ulcerations and easy contact bleeding (Figure 2). Pathology report of biopsy was acute and chronic inflammation. Patient reported that he used hot water enema to clean his rectum frequently [5].

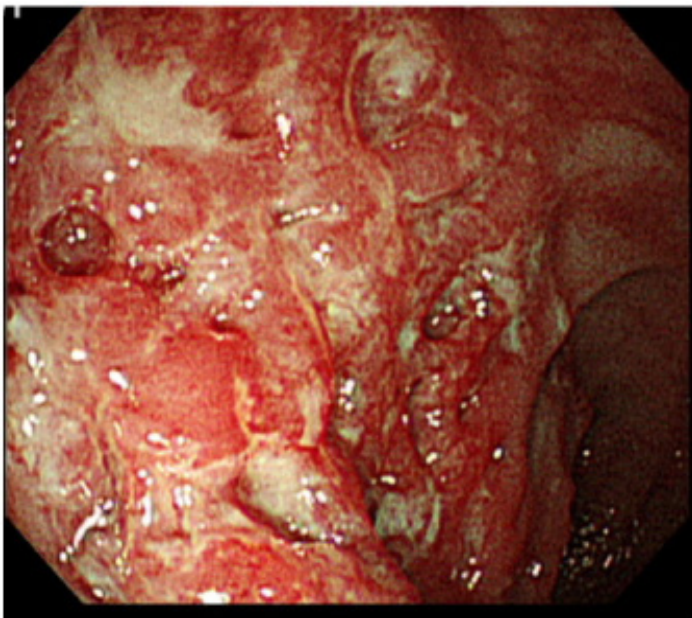


Figure 2: Flexible sigmoidoscopy revealed friable edematous mucosa of rectum with multiple ulcerations and easy contact bleeding.

4.4. Case 3

A 72-year-old female, presented with tenesmus for a few months. She had a history of radical proctectomy 4 years and 3 months ago for Duke's C rectal cancer. Colonoscopy revealed rectal ulcerations with necrosis (Figure 3). Pathology of biopsy revealed inflammatory exudate. Enema-related thermal injury was suspected. Patient reported that she used hot coffee enema in order to avoid recurrence of carcinoma.

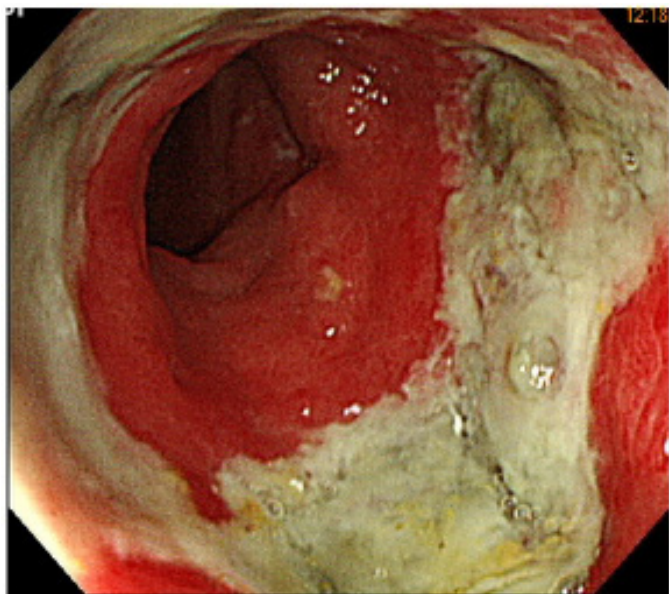


Figure 3: Colonoscopy revealed rectal ulcerations with necrosis.

4.5. Case 4

A 67-year-old male was admitted due to rectal bleeding, dizziness, and general weakness for a few weeks. His hemoglobin was 3.6 g/dL (normal range of 13-18 g/dL). Colonoscopy by a gastroenterologist

was reported as granulation in the rectum. Pathology report of biopsy showed granulation tissue.

Panendoscopy revealed multiple small A1-2 ulcers in the antrum. He was treated conservatively and was then discharged without knowing exact cause of colitis (Figure 4). He was then seen by a colorectal surgeon in the clinic 10 days later. Proctitis caused by hot water was suspected. Patient reported that he used hot water enema for relief of constipation before this episode of colitis [6].

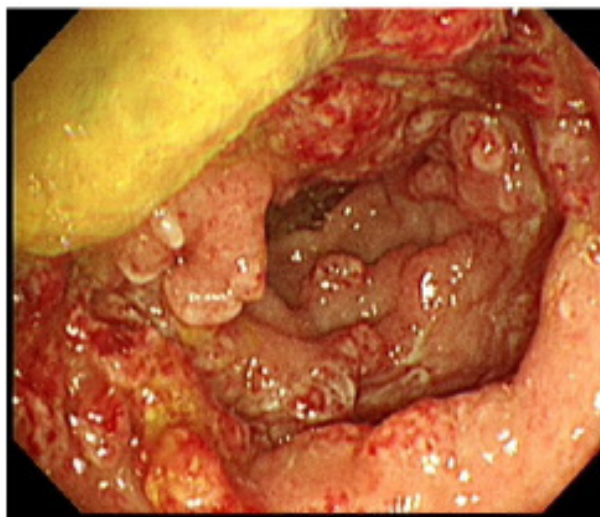


Figure 4: Colonoscopy was reported as granulation in the rectum.

4.6. Case 5

A 21-year-old male presented with rectal bleeding for a few days. Colonoscopy by a colorectal surgeon revealed cluster of polypoid lesion at low rectum at a level from 3~5 cm from anal verge (Figure 5). Transrectal polypectomy was performed and pathology revealed hyperplastic polyp with erosion. Colonoscopy 4 years and 3 months later by another colorectal surgeon revealed friable, edematous, hyperemic mucosa with easy contact bleeding and granulation tissue in the low rectum (Figure 6). Patient reported that he was continuously using hot water enema unaware that hot water was the cause of his colitis [7].

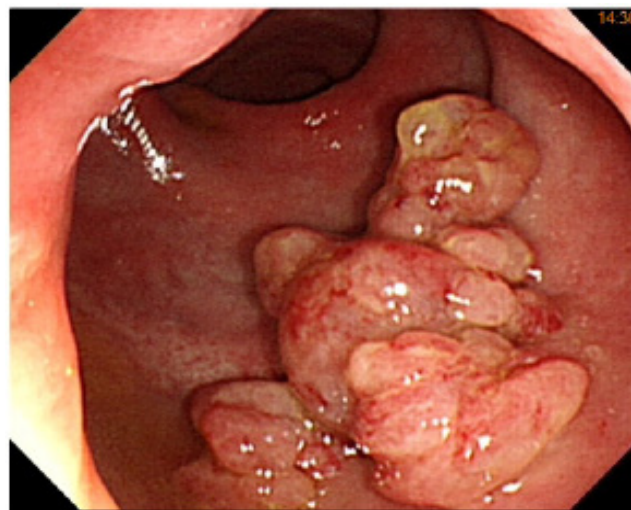


Figure 5: Colonoscopy revealed cluster of polypoid lesion at low rectum at a level from 3~5 cm from anal verge.

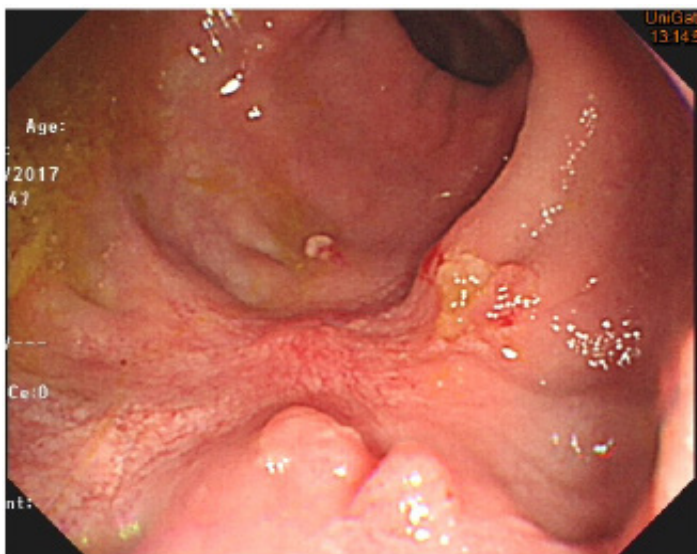


Figure 6: Colonoscopy revealed friable, edematous, hyperemic mucosa with easy contact bleeding and granulation

5. Discussion

The causes of scalding injury to rectum from the series include a few kinds of uses:

- Use hot water for treatment of constipation.
- Use hot water to clean rectum after anal sex in men who have sex with men.
- Use hot water to clean rectum to avoid recurrence of cancer in those who had history of colorectal cancer.
- Use hot coffee enemas for an anti-cancer effect, to increase energy, or to remove parasite from the digestive tract.
- Inappropriate use of electronic bidet spray, especially in those who have anal incontinence, those condition might include too strong of jet flow, too high of flow temperature, malfunction of temperature adjustment, and placing bidet head into the rectum. It is well known that mechanoreceptors are distributed throughout the gastrointestinal tract. The Anal area is rich in thermoreceptors, which cause contraction and withdrawal whenever a hot substance comes into contact with the anal canal. Thermodamage to the lower gastrointestinal tract is extremely rare, partly because the only objects introduced into the rectum are through voluntary actions, mostly with therapeutic intention and only a few related to other behavior [8].

Enemas have long been used for bowel cleansing and for constipation. While the idea of rectal cleansing dates back to the Ancient Egyptians, the notion of caffeine as an enema-related substance is relatively new. It was conceived in 1917, and appeared in the Merck Manual until 1972. In 1920, German scientists investigated caffeine's effect on the bile duct and small intestines. Max Gerson proposed that coffee enemas had a positive effect on the gastrointestinal tract. Gerson stated that coffee enemas had positive effects on patients

with tuberculosis and later even those with cancer. He told his patients often that the "coffee enemas are not given for the function of the intestines but for the stimulation of the liver."

Some proponents of alternative medicine have claimed that coffee enemas have an anti-cancer effect by "detoxifying" metabolic products of tumors. However, there is no scientific evidence to support any anti-cancer effect of coffee enemas. Additionally, the caffeine in the coffee enema may lead to caffeine addiction; coffee enema might also cause side effects and dangers including re-used (instead of single use) enema kits resulting in a tissue injury, infection, sepsis, electrolyte imbalance, hyponatremia, dehydration, coloproctitis, salmonella infection, brain abscess, pleural effusion, and heart failure. Use of hot liquid in the rectum could result in serious internal burns and rectal perforation.

Bidet is a French loanword. Bidet is a plumbing fixture or type of sink intended for washing the genitalia, perineum, inner buttocks, and anus of the human body. A plumbing fixture is an exchangeable device which can be connected to a plumbing system to deliver and drain water. Bidet is typically installed in a bathroom. Lower-cost add-ons combining a toilet seat and "electronic bidet" are becoming increasingly popular as well. Inappropriate use of electronic bidet spray, especially in those who have anal incontinence, might include too strong of jet flow, too high of flow temperature, malfunction of temperature adjustment, and placing bidet head into the rectum.

Colitis caused by hot water might be associated with complications such as rectal burn, permanent rectal stricture and bowel perforation, or even death. It is important to educate patients not to use any hot water for enema at all. Patients having colitis caused by hot water might be misdiagnosed as other type specific or non-specific colitis by general practitioners or even by specialists. It is essential to alert physician to differentiate colitis caused by hot water with other types of colitis or malignancies [9].

6. Conclusion

Scalding injury by hot water is not a commonly seen disease. However, scalding injury might increase in modern days due to herbal remedies used by holistic practitioners. Maladjustment and malfunction of electronic bidet might increase chance of scalding injury. Early diagnosis and appropriate management is essential for patient's outcome.

References

1. Jimenez-Ballester MA, Bebia-Conesa P, Mengual-Ballester M, Carrillo-García M, Miguel-Perello J, Perez-Cuadrado-Martínez E et al. Necrotic left colitis due to hot water enema. *Rev Esp Enferm.* 2014; 106: 542-3.
2. Kim S, Cha JM, Lee CH, Shin HP, Park JJ, Joo KR et al. Rectal perforation due to benign stricture caused by rectal burns associated with hot coffee enemas. *Endoscopy* 2012; 44: E32-E33
3. Sashiyama H, Hamahata Y, Matsuo K, Akagi K, Tsutsumi O, Nakajima

- Y et al. Rectal burn caused by hot-water coffee enemas. *Gastrointest Endosc.* 2008; 68: 1008-9.
4. Jones LE, Norms WE. Rectal burn induced by hot coffee enemas. *Endoscopy.* 2010; 42: E26.
 5. Kye BH, Kim HJ, Lee KM, Cho HM. Intractable rectal stricture caused by hot water enema. *J Korean Surg Soc.* 2011; 81: 350-4.
 6. Sternberg A, Iuchtman M, Auslander L, Sternberg E, Robinson S, Fireman Z et al. Acute proctitis after a hot-water enema. *J Clin Gastroenterol.* 1995; 20: 80-2.
 7. Manjoo, Farhad (April 29, 2015). Electronic bidet toilet seat is the luxury you won't want to live without. *The New York Times.* Retrieved. 2017; 05: 10.
 8. Tom Mossey. Top 10 dangers of the coffee enema. 2007.
 9. Eisele JW, Reay Dt. Deaths related to coffee enemas. *JAMA* 1980; 244: 1608-9.