

## A Role for Esophagectomy in Patients with Definitively Treated Solitary Oligometastasis and Worsening Dysphagia: A Case Series

Awe AM, BS and Maloney JD\*

Department of Surgery, Division of Cardiothoracic Surgery, University of Wisconsin School of Medicine & Public Health, Madison, Wisconsin, USA

### \*Corresponding author:

James D Maloney,  
Department of Surgery, Division of  
Cardiothoracic Surgery, University of  
Wisconsin School of Medicine & Public Health,  
Madison, Wisconsin, USA,  
E-mail: maloney@surgery.wisc.edu

Received: 08 Mar 2021

Accepted: 24 Mar 2021

Published: 30 Mar 2021

### Copyright:

©2021 Awe A and Maloney JD, This is an open access article distributed under the terms of the Creative Commons Attribution License, which permits unrestricted use, distribution, and build upon your work non-commercially.

### Citation:

Awe A and Maloney JD. A Role for Esophagectomy in Patients with Definitively Treated Solitary Oligometastasis and Worsening Dysphagia: A Case Series. Japanese J Gastro Hepato. 2021; V6(6): 1-3

### Keywords:

Esophagus; Esophageal adenocarcinoma; Esophageal cancer; Oligometastasis; Esophagectomy

### 1. Abstract

The incidence of esophageal adenocarcinoma and its oligometastatic dissemination to non-conventional sites is increasing. We report three patient cases of stage IV esophageal adenocarcinoma where oligometastatic disease was identified following neoadjuvant chemoradiation. In one patient, worsening dysphagia and complete excision of a cutaneous oligometastasis warranted esophagectomy for a stage IV adenocarcinoma. Historically, evidence of metastatic disease precludes surgical resection, however, we suggest a potential role of resection in patients with persistent or worsening dysphagia and aggressively treated oligometastatic disease of skin and soft tissues.

### 2. Introduction

Esophageal carcinoma exists in two primary histopathologic types: Esophageal Adenocarcinoma (EAC) and Esophageal Squamous Cell Carcinoma (ESCC). Incidence of esophageal carcinoma is decreasing largely due to a decline in ESCC, but EAC incidence is steadily increasing, particularly in Western societies [1]. From 2004 - 2015 the incidence of EAC was 3.2 per 100,000 with metastatic stage IV EAC predominating (37%) stage at diagnosis [2]. Common sites of EAC metastases include lung, liver, adrenal glands, and brain. It is less common for EAC metastases to disseminate to soft tissues with roughly 3.5% of non-conventional metastases occurring in cutaneous tissues and skeletal muscles [3]. However, there is an increasing body

of literature that describes metastatic EAC to soft tissue sites [4-6]. We report three cases of biopsy-proven oligometastatic disease in patients previously diagnosed with EAC.

### 3. Case Reports

In the last year, patients with previously diagnosed EAC and evidence of oligometastatic disease presented to or were identified at our institution.

#### 3.1. Case 1

Patient 1 is a 54-year-old male with history of soft-solid food dysphagia at time of presentation who was diagnosed with a cT3 cN1 cM0 (stage III) distal EAC who underwent neoadjuvant chemoradiation with carboplatin and paclitaxel and 50.4 Gray (Gy). Re-staging positron emission tomography/computed tomography (PET/CT) detected a new (18) F-fluorodeoxyglucose (FDG)-avid lesion in the left vastus medialis consistent with oligometastatic EAC on ultrasound-guided fine needle aspiration (Figure 1A). Evidence of metastatic disease advanced staging to stage IV b. The patient had improved dysphagia at time of restaging PET. Operative intervention was not pursued and salvage chemotherapy with FOLFOX and bevacizumab followed by paclitaxel and ramucirumab was initiated.

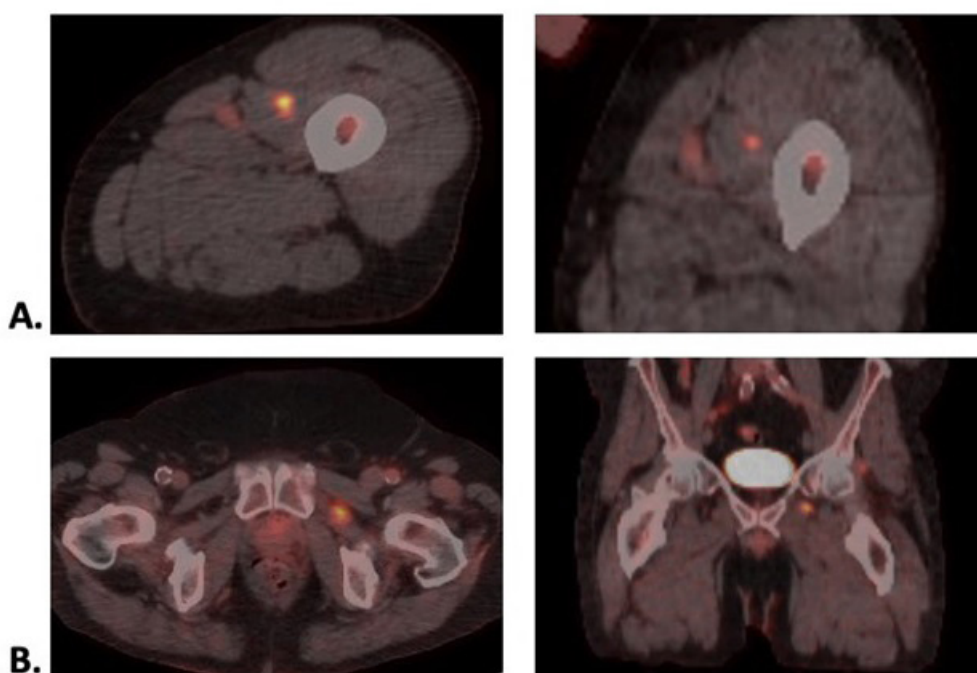
#### 3.2. Case 2

Patient 2 is a 68-year-old male with history of hard-solid food dysphagia with previously diagnosed cT3 cN0 cM0 (stage II) distal EAC. This patient underwent neoadjuvant chemoradiation with

carboplatin and paclitaxel and 50.4 Gy. Following neoadjuvant therapies, a soft-tissue lesion of the chin was noted and concerning for basal cell carcinoma. Shave biopsy results were consistent with oligometastatic EAC. This patient then underwent excisional biopsy of an oligometastatic chin lesion followed by FOLFOX chemotherapy. Given worsening dysphagia despite chemotherapy and aggressive locoregional treatment of the oligometastatic lesion a minimally invasive McKeown esophagectomy with mediastinal and abdominal lymph node dissections with J-tube placement was conducted. Surgical pathology demonstrated moderately differentiated adenocarcinoma that extends to the adventitia and 1/40 lymph nodes positive for carcinoma (ypT3 ypN1 ypM0; stage IIIb).

### 3.3. Case 3

Patient 3 is 60-year-old male with history of progressive dysphagia with a previously diagnosed cTx cN1 cM0 (stage indeterminate) distal EAC. Distal strictures limited complete staging with endoscopic ultrasound. This patient underwent neoadjuvant chemoradiation with carboplatin and paclitaxel, and 41.4 Gy. Re-staging PET/CT demonstrated persistent left external obturator muscle FDG-avidity previously thought to be a reactive lymph node or focal muscle strain (Figure 1B). Computed tomography-guided core needle biopsy demonstrated pathology consistent with the primary EAC. Distant oligometastasis advanced staging to a stage IV b EAC. At this time, dysphagia to hard-solid foods was stable and planned surgery was discontinued.



**Figure 1:** Patient imaging demonstrating evidence of metastatic disease of EAC. Re-staging PET/CT demonstrating an FDG-avid lesion in the left vastus medialis muscle in axial and coronal planes (A). Re-staging PET/CT demonstrating an FDG-avid lesion in the left external obturator muscle in axial and coronal planes (B). EAC: esophageal adenocarcinoma. CT: computed tomography. PET: positron emission tomography. FDG: (18) F-fluorodeoxyglucose.

## 4. Discussion

Metastatic disease in advanced EAC is not uncommon. However, the locations of the metastatic lesions in the patients described are uncommon. Shaheen and colleagues 2017 have described unorthodox spread of EAC in a systematic review [3]. Our intent is to describe a trend in oligometastatic spread to skin and skeletal muscle and discuss the challenges in identifying which patients with oligometastatic stage IV EAC may benefit from resection.

Our patients presented with varying levels of dysphagia. Patients 1, 2, and 3 exhibited interval resolution of dysphagia, worsening dysphagia, and stable dysphagia following neoadjuvant chemoradiation, respectively. Each patient received standard neoadjuvant chemotherapy with carboplatin/paclitaxel or FOLFOX

with concurrent radiation therapy. In all of the patients presented, oligometastatic disease was diagnosed shortly after completion of neoadjuvant chemoradiation suggesting advancement of disease despite neoadjuvant therapies.

Surgery was not pursued with the emergence of oligometastatic disease in the patients with stable to improving dysphagia and/or difficult to definitively treat oligometastatic lesions of skeletal muscles. The second patient with oligometastatic disease to the soft tissue of their chin had complete resection of the chin lesion, confirmation of residual disease within the esophagus, and worsening dysphagia despite neoadjuvant chemoradiation. Resection was pursued because the risks of esophagectomy failed to outweigh the patient's worsening dysphagia and the patient had absent evidence of

other oligometastatic disease. The subsequent question that arises is what factors should be considered when deciding whether to pursue surgical resection in patients with stage IV EAC. In a retrospective analysis of patients with stage IV esophageal cancer who underwent esophagectomy, 88.5% of patients had metastatic disease identified intra-operatively, and 11.5% of patients had known metastatic disease prior to surgery [7]. There was no reported statistical significance in 5-year overall survival in these two groups. However, patients with known pre-operative metastatic disease had 28% 5-year overall survival compared to 4% in patients with metastatic disease identified intra-operatively. This suggests that neoadjuvant therapy confers a survival advantage in patients with esophageal cancer. It follows that definitive treatment of oligometastatic disease may also confer a survival advantage, however, this area of study is poorly understood and warrants further investigation.

These cases demonstrate how we can think about esophagectomy in stage IV EAC, given the potential morbidity of the procedure. We would differentiate these cases from the standard “salvage esophagectomy” for patients with residual disease after definitive non-operative therapy. The second patient example highlights that surgical resection may be appropriate in patients with a solitary oligometastatic lesion that can be definitively treated with symptoms, like dysphagia, guiding the decision for resection. Surgical resection is likely not warranted in patients without persistent or worsening dysphagia, and difficult to treat solitary oligometastatic lesions as in Patient 1. Surgical resection may be warranted to a lesser extent in patients with difficult to definitively treat solitary oligometastatic lesions despite presence of dysphagia, as in Patient 3 with metastatic spread to the left external obturator muscle. Taken together, the ability to definitively treat a solitary oligometastatic lesion to skin or skeletal muscle with a patient’s presence and severity of dysphagia may be used to help guide the decision to pursue esophagectomy. Further research is recommended to determine which patients with EAC are poor responders to neoadjuvant chemoradiation and may benefit from early resection, and when esophagectomy is appropriate in patients with stage IV EAC.

## References

1. He H, Chen N, Hou Y, Wang Z, Zhang Y, Zhang G et al. Trends in the incidence and survival of patients with esophageal cancer: A SEER database analysis. *Thorac Cancer*. 2020; 11: 1121-8.
2. Then EO, Lopez M, Saleem S, Gayam V, Sunkara T, Culliford A et al. Esophageal Cancer: An Updated Surveillance Epidemiology and End Results Database Analysis. *World J Oncol*. 2020; 11: 55-64.
3. Shaheen O, Ghibour A, Alsaïd B. Esophageal Cancer Metastases to Unexpected Sites: A Systematic Review. *Gastroenterol Res Pract*. 2017; 1657310-22.
4. Tarantino IS, Tennill T, Fraga G, Fischer R. Cutaneous metastases from esophageal adenocarcinoma on the scalp. *Cutis*. 2020; 105; E3-E4.
5. Sohda M, Ojima H, Sano A, Fukai Y, Kuwano H. Primary esophageal adenocarcinoma with distant metastasis to the skeletal muscle. *Int Surg*. 2014; 99; 650-5.
6. El Abiad JM, Hales RK, Levin AS, Morris CD. Soft-Tissue Metastases from Esophageal Cancer. *J Gastrointest Surg*. 2019; 23: 1721-8.
7. Saddoughi SA, Reinersman JM, Zhukov YO, Taswell J, Mara K, Harmesen SW et al. Survival After Surgical Resection of Stage IV Esophageal Cancer. *Ann Thorac Surg*. 2017; 103: 261-266.