

A Rare Cause of Intestinal Obstruction: Case Report of an Abdominal Cocoon Syndrome in a Middle Aged Man from the Mediterranean Region

Jibaii S, Nasser Y, Bouhairie MM, Bleibel L and Hotayt B*

Gastroenterology Department, Al Rassoul Al Aazam Hospital, Lebanon

*Corresponding author:

Bilal Hotayt,
Gastroenterology Department, Al Rassoul Al
Aazam Hospital,, Lebanon, Tel: 96176724004;
E-mail: bilal.hotayt@hotmail.fr

Received: 08 Jan 2022

Accepted: 21 Jan 2022

Published: 28 Jan 2022

J Short Name: JJGH

Copyright:

©2022 Hotayt B. This is an open access article distributed under the terms of the Creative Commons Attribution License, which permits unrestricted use, distribution, and build upon your work non-commercially.

Citation:

Hotayt B, A Rare Cause of Intestinal Obstruction: Case Report of an Abdominal Cocoon Syndrome in a Middle Aged Man from the Mediterranean Region. Japanese J Gastro Hepato. 2022; V8(3): 1-4

Keywords:

Abdominal cocoon syndrome; Intestinal obstruction; Case report

1. Abstract

1.1. Introduction: Abdominal cocoon syndrome is a rare condition that refers to total or partial encapsulation of the small intestines leading to recurrent bowel obstruction. It usually affects young ladies from tropical and subtropical area.

1.2. Methods: we report a middle aged man, from the Mediterranean region, presenting with small bowel obstruction, with history of recurrent similar episode.

1.3. Results: after failure of conservative treatment, surgical exploration showed a thick fibrous peritoneal membrane wrapping the small bowel in a concentric fashion with some adhesions. The pathology of this resected fibrous membrane confirmed the diagnosis of an abdominal cocoon syndrome.

1.4. Conclusion: From the atypical presentation of our case, we can conclude that though rare, this condition must be kept in mind when considering the differential diagnosis of idiopathic intestinal obstruction in any adult and therefore the decision of a surgical exploration should not be differed in the appropriate context, especially in the light of the condition's benign nature and favorable prognosis.

1.5. Background: Abdominal cocoon syndrome is a rare condition that refers to total or partial encapsulation of the small intestines by a fibro-collagenous membrane with local inflammatory infiltrate leading to acute, subacute or chronic bowel obstruction [1]. It also has been described as "encapsulating peritoneal sclerosis", "sclerosing encapsulating peritonitis" and in Latin "peritonitis chronica fibrosaincapsulata" [1, 2].

2. Case Report

A 52 years old Lebanese man, nonsmoker, presented to the emergency department for severe diffuse abdominal pain. His pain started one week ago, increasing in intensity and was associated with post-prandial nausea and vomiting and one episode of undocumented fever. These symptoms were refractory to symptomatic treatment. Patient mentioned a chronic history of similar symptoms and he had recurrent admissions for same complaints in different health care centers with diagnosis of recurrent small bowel obstruction. History goes back to 15 years ago during which he had 5 episodes of the same illness. He had no previous medical or surgical history. On physical examination patient was conscious, cooperative and well oriented to time, place and person. He looked ill and dehydrated. Vital signs were within normal range. Bowel sounds were positive but slow. Abdomen examination showed mild distention with decrease bowel sound, and diffuse tenderness. Abdominal-pelvic x-ray (Figures 1) showed multiple air-fluid levels. A primary diagnosis of intestinal obstruction was made. Blood was drawn for laboratory tests (Table 1) and turned normal except for leucocytosis (11,400) with left shift (PMNs: 81%), and mildly elevated C-reactive protein (2.5). CT scan of abdomen and pelvis was done with both PO and IV contrast showed that contrast opacified the gastric lumen and upper jejunal loops but didn't pass to the mid jejunum till the ileum, in addition to dilatation of small bowels and mild ascites. The findings were confirmed by a MRE (Figure 2 and 3). The patient refused the placement of nasogastric tube, and was not improving during his medical ward stay. So, a decision was tak-

en in cooperation with general surgeon to carry out an exploratory laparotomy. At laparotomy, a thick fibrous peritoneal membrane was wrapping the small bowel in a concentric fashion with some adhesions (Figure 4 and 5). This membrane was carefully excised with lysis of adhesions. The underlying bowel was examined and found to be healthy without any need of further intervention. The tissue resected was sent to the pathology that showed benign pieces of thick fibrosis and fibro-membranous tissue focally lined by flat simple epithelial lining. The cultures taking from the peritoneal fluid intra-op turned negative. Based on all these results, the patient was diagnosed with abdominal cocoon.

Patient was transferred to medical ward postoperatively; his stay was very smooth. Surgical dressing was done daily and showed clean wound. Fluid diet was started 12 hours post-op. Repeated scan abdomen showed resolution of bowel dilatation. He was discharged home after one week with scheduled surgical outpatient follow up after 1 month.

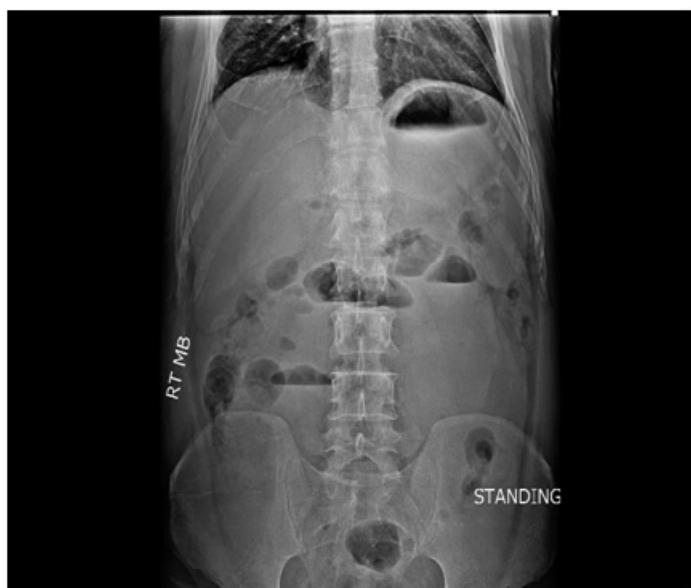

Figure 1: Standing abdominal-pelvic x-ray showing multiple air-fluid levels.

Table 1: Laboratory tests results

Lab test	Result	Normal range
WBC count (k/microliter)	11.4	4-11
Neutrophils (%)	81.9	37-75
Lymphocytes (%)	5.7	10-50
Hemoglobin (g/dl)	12.8	13.5-18
Hematocrit (%)	41.7	42-52
Platelets count (k/microliter)	212	140-440
Creatinine (mg/dl)	1.07	0.6-1.3
CRP (mg/dl)	2.5	0-1
Na (mmol/l)	137	130-140
K (mmol/l)	4	3.6-5.7
Cl (mmol/l)	101	99-111
CO2 (mmol/l)	24	20-28
INR	1.01	0.9-1.15
PTT (sec)	32	21-34

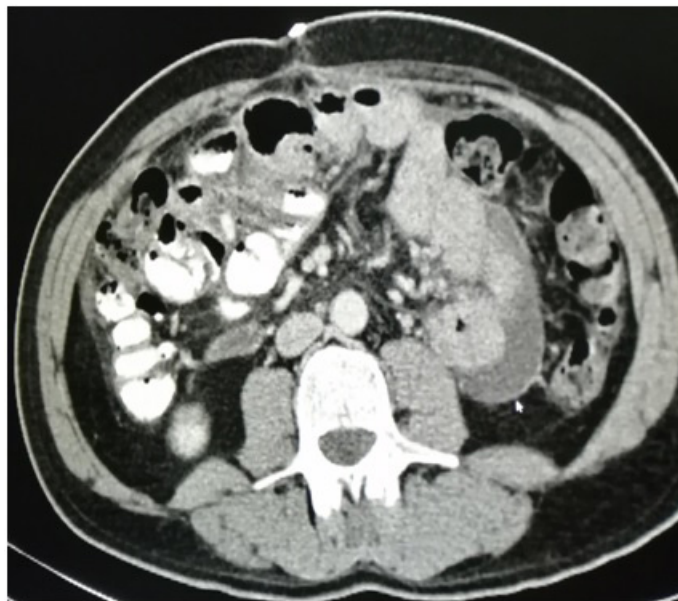


Figure 2: Scan abdomen-pelvis showing absence of contrast beyond the jejunum.

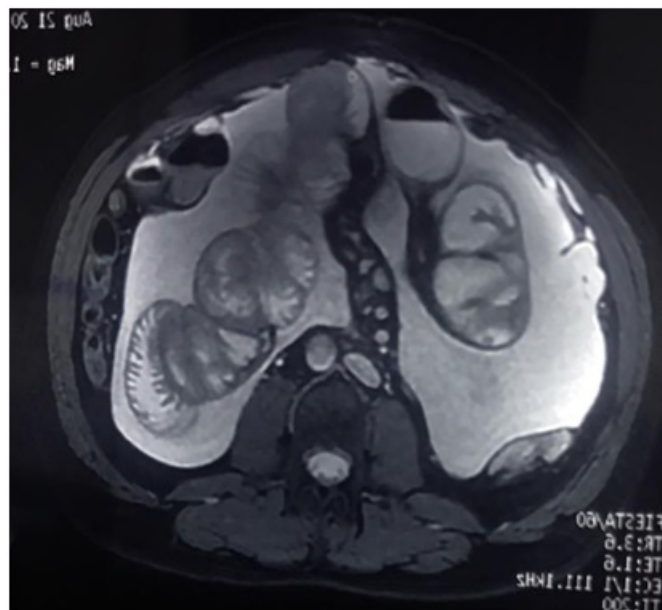


Figure 3: MRE findings: Cluster of collected bowel segments in the upper and lower abdomen encased within a thickened membrane suggesting encapsulating sclerosing peritonitis.

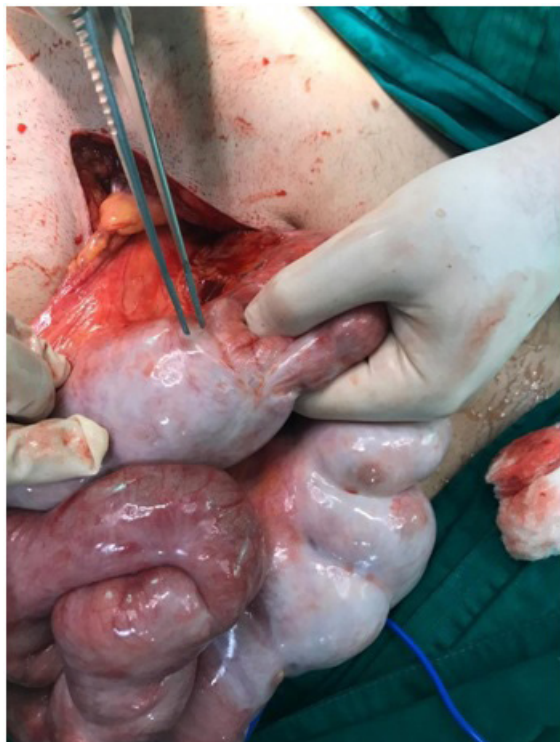

Figure 4: At laparotomy, a thick fibrous peritoneal membrane was wrapping the small bowel with adhesions.

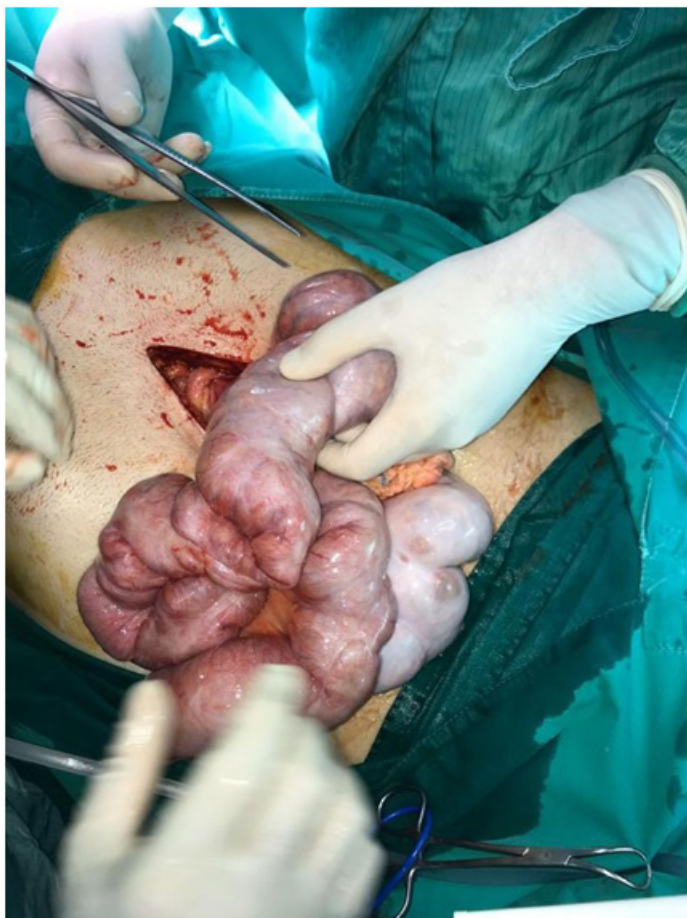

Figure 5: At laparotomy, a thick fibrous peritoneal membrane was wrapping the small bowel with adhesions.

3. Discussion

Abdominal cocoon, a condition first described in 1907 [1], is a very rare cause of intestinal obstruction. The name arises from the structural nature of the condition which consists of a fibrous membrane encompassing the small bowels partially or totally like a butterfly's cocoon [2]. Clinically, this structural membrane causes a picture of acute or chronic intestinal obstruction. The etiology is unknown. The condition, when idiopathic, usually affects young and adolescent girls in tropical and subtropical countries [3] (especially Pakistan, China and India) and is called primary sclerosing encapsulating peritonitis [4]. Some secondary cases were described in patients affected by abdominal tuberculosis, on peritoneal dialysis and on autopsies of cirrhotic patients, on beta blockers, recurrent peritonitis, liver transplantation, ventriculo-peritoneal shunts [5]. It is diagnosed on laparotomy by visualizing of the fibrous membranes surrounding the intestines and treatment is surgical removal of the membrane and adhesions. Our patient is a middle aged man, who presented in a picture of small bowel obstruction complaining of severe diffuse abdominal pain, nausea and vomiting with no identifiable etiology. The cause was only unraveled after laparotomic exploration triggered by the findings of multiple air-fluid levels, pointing to small bowel obstruction on abdominal imaging. The idea of being idiopathic in a middle aged male, from the Mediterranean region makes our case different from the typical scenario of idiopathic abdominal cocoon that affects young ladies in tropical and subtropical regions.

In terms of the patient's demographic and personal traits, our case is consistent with the findings stated by "sharma et al." (2013) and "karona et al." (2021) about the conditions tendency to affect middle-aged males [6, 7]. However, it differs from what "Calvo et al." stated about it affecting young and adolescent girls in tropical and sub-tropical countries (especially Pakistan, China and India) [8]. In terms of signs and symptoms, our case presented with severe abdominal pain, nausea and vomiting all of which are cardinal features mentioned in the cases reported by "okada et al.", "sharma et al.", "calvo et al." and "karona et al." [6, 7, 8, 3]. But other case reports mentioned more serious manifestations including malnutrition and weight loss [3]. In terms of risk factors, our patient is a middle-aged man previously healthy with no previous medical or surgical history. However, "okada et al." mentioned a middle-aged female with long-standing history of peritoneal dialysis that contributed to the development of her condition [8]. Moreover, "Sharma et al." and "karona et al." mentioned middle-aged men with prior histories of appendectomy procedures that presented with the condition a short time afterward [6, 7]. This sheds the light on the importance of considering such diagnosis in previously healthy individuals without risk factors for abdominal cocoon syndrome. In terms of management and prognosis, our case had exploratory laparotomy and after removal of the thick fibrous membrane the patient condition improved and was discharged a couple of days afterward. This is similar to that reported by "sharma et al.", "okada et al." and "karona et al."

[6, 7, 8]. However, “Okada et al.” reported that the patient eventually died from septicemia [8]. In Summary, the fact of encountering an idiopathic encapsulating peritoneal sclerosis in a middle-aged man, from the Mediterranean descent, is what makes our case different from the typical scenario that affects young ladies in tropical and subtropical regions and other patients with possible risk factors [6, 8]. From the atypical presentation of our case, we can conclude that though rare, this condition must be kept in mind when considering the differential diagnosis of idiopathic intestinal obstruction in any adult and therefore the decision of a surgical exploration should not be differed in the appropriate context, especially in the light of the condition’s benign nature and favorable prognosis.

4. Funding

This research did not receive any specific grant from funding agencies in the public, commercial, or not-for-profit sectors.

5. Ethical Approval

The study type is exempt from ethical approval.

6. Conflict of Interest

The authors declare that they have no conflict of interest.

References

1. Sahoo SP, Gangopadhyay AN, Gupta DK, Gopal SC, Sharma SP, Dash RN, et al. Abdominal cocoon in children: a report of four cases. *Journal of pediatric surgery*. 1996; 31(7): 987-988.
2. Foo KT, Ng KC, Rauff A, Foong WC, Sinniah R. Unusual small intestinal obstruction in adolescent girls: The abdominal cocoon. *Journal of British Surgery*. 1978; 65(6): 427-30.
3. Calvo P, Suraz M, Blanchar R. Abdominal cocoon syndrome: A diagnostic and therapeutic challenge. Case report. *Cir Esp*. 2013; 22: 93(7): e61-2.
4. Xu P, Chen LH, Li YM. Idiopathic sclerosing encapsulating peritonitis (or abdominal cocoon): a report of 5 cases. *World J Gastroenterol*. 2007; 13(26): 3649-3651.
5. Machado NO. Sclerosing Encapsulating Peritonitis: Review. *Sultan Qaboos Univ Med J*. 2016; 16(2): e142-51.
6. Sharma D, Nair RP, Dani T, Shetty P. Abdominal cocoon-A rare cause of intestinal obstruction. *International journal of surgery case reports*. 2013; 4(11): 955-957.
7. Karona P, Blevrakis E, Kastanaki P, Tzouganakis A, Kastanakis M. Abdominal Cocoon Syndrome: An Extremely Rare Cause of Small Bowel Obstruction. *Cureus*. 2021; 13(4).
8. Okada K, Onishi Y, Oinuma T, Nagura Y, Soma M, Saito S, et al. Sclerosing encapsulating peritonitis: regional changes of peritoneum. *Nephron*. 2002; 92(2): 481-483.