

Acute Perforation of a Prior Small Bowel Anastomosis Secondary to CMV Enteritis in a Newly-Diagnosed AIDS Patient

Brian Diskin¹, Weiguo Liu² and Cris MK Malino^{1*}

¹Division of Acute Care Surgery, Departments of Surgery, New York University School of Medicine, 550 First Avenue, New York, NY 10016

²Department of Pathology New York University School of Medicine, 550 First Avenue, New York, NY 10016

*Corresponding author:

Cris MK Malino,
Division of Acute Care Surgery, Department of Surgery,
NYU Langone Health 550 First Avenue, Suite 1230, New
York, NY 10016 New York, NY 10016

Received: 13 Aug 2023

Accepted: 03 Oct 2023

Published: 10 Oct 2023

J Short Name: JJGH

Copyright:

©2023 Cris MK Malino, This is an open access article distributed under the terms of the Creative Commons Attribution License, which permits unrestricted use, distribution, and build upon your work non-commercially.

Citation:

Cris MK Malino. Acute Perforation of a Prior Small Bowel Anastomosis Secondary to CMV Enteritis in a Newly-Diagnosed AIDS Patient. *J Gastro Hepato.* 2023; V10(2): 1-4

Keywords:

CMV; Enteritis; AIDS; Small Bowel Perforation

1. Abstract

Poorly controlled human immunodeficiency virus (HIV) infection can result in progression to acquired immunodeficiency syndrome (AIDS). Opportunistic infection in AIDS patients can be severe, resulting in life-threatening encephalitis, meningitis, retinitis, esophagitis, and enteritis. Here, we describe the unusual case of a 50 year-old male with newly diagnosed AIDS presenting to the ER with pneumoperitoneum and sepsis secondary to perforation at his prior small bowel anastomotic site due to Cytomegalovirus. While undergoing workup for weight loss, an EGD revealed esophageal ulcerations. Biopsies were consistent with CMV. Serum CMV showed 1,319 copies/mL. These findings were followed with a positive HIV-1 antibody test. Notably, the patient had a history of a small bowel obstruction, 35 years prior, requiring exploratory laparotomy, small bowel resection and ostomy creation (status post subsequent reversal). He presented to our urban academic medical center with abdominal pain and fevers and was found to have pneumoperitoneum and perforation of his prior small bowel anastomosis. After resection and ileostomy formation, the pathology revealed active cMV on immunohistochemical stains. The report includes relevant and imaging and literature review on this rare presentation.

2. Introduction

CMV enteritis is a rare condition, but typically found in immunocompromised patients, especially those who chronically take steroids, chemotherapy, have undergone transplantation, or those with HIV

complicated by AIDS [1, 2]. Common complications of AIDS include opportunistic infections of the retina, respiratory system, nervous system, and gastrointestinal (GI) tract [3]. The colon is the most commonly affected site, and CMV enteritis affecting the small bowel is unusual, although symptoms may include life-threatening hemorrhage or perforation [4]. We report the case of 50 year-old male with a history of a prior small bowel resection who was admitted with abdominal pain, fevers, and a recent diagnosis of HIV/AIDS. He was found to have CMV enteritis complicated by perforation at his remote small bowel anastomosis requiring urgent surgical intervention.

3. Case Report

A 50 year-old man presented with a two-month history of a 60 pound unintentional weight loss, lower abdominal pain, and early satiety. Medical history was only significant for asthma, and surgical history included a laparotomy for obstruction requiring small bowel resection in 1985. He had no history of immunodeficient conditions, steroid intake, or chemotherapy. He subsequently underwent esophago-gastroduodenoscopy and was found to have an esophageal ulcer, with biopsies positive for CMV and candida. After referral to an infectious disease specialist, his work-up revealed a new diagnosis of HIV/AIDS. CD4+ T cell count was 15 cell/uL, and the HIV-1 viral load was 179,000 copies/mL. CMV IgG was >8.0 AI and CMV DNA was 1,319 copies/mL. Fecal occult blood was checked, and found to be positive. The patient remained an outpatient, and started valganciclovir as well as fluconazole. One week later, the patient presented to the

Emergency Department with one day of acute right lower quadrant abdominal pain. In the ED, he was found to be febrile to 102 degrees F, tachycardic to 120 beats/minute, with a WBC of 5.5 (10^3 u/L). Computed tomographic (CT) cross sectional imaging was obtained and demonstrated lymphadenopathy and as well as ileal thickening (Figure 1). The patient was admitted for fluid resuscitation, observation, and was started on intravenous antibiotics. On hospital day two, the patient developed acutely worsening abdominal pain, tachycardia, and tachypnea. A repeat CT scan was obtained, which demonstrated new pneumoperitoneum, an abscess, and small bowel dilatation associated with the patient's prior small bowel anastomosis (Figure 2a-c). The patient was emergently taken to the operating room for exploratory laparotomy. Extensive adhesions were encountered and lysed, revealing an area of thickened and dilated small bowel anastomosis

with surrounding succus and a clear area of perforation. This area of small bowel was resected, and the patient was left in discontinuity and taken to the Surgical Intensive Care Unit for further resuscitation. In the following days, he was subsequently taken back to the operating room for washout, end ileostomy creation, and abdominal closure. Small bowel anastomosis was not attempted given the patient's sepsis, abdominal contamination, and poorly controlled AIDS. He was continued on IV valganciclovir for a three week course and was subsequently discharged home without complication. CMV enteritis is a pathologic diagnosis. In this case, the pathologic sample obtained in the operating room demonstrated ischemic ileitis and ulceration, consistent with CMV enteritis. There was a defect consistent with perforation. Mucosal ulceration (Figure 3a) and CMV staining identified by immunohistochemistry (Figure 3b-c).

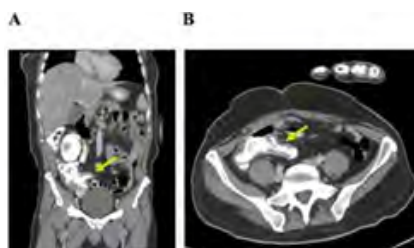


Figure 1: a: The distal/terminal ileum and cecum demonstrated wall thickening consistent with enteritis/colitis on the initial abdominal CT scan. b: Distal/terminal ileal wall thickening can be seen on axial CT imaging.

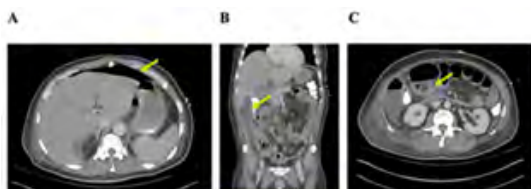


Figure 2: On hospital day 2, a repeat abdominal CT scan revealed large volume pneumoperitoneum (a), as well as a right pericolic abscess (b), and small bowel dilatation associated with the patient's prior small bowel anastomosis (c).

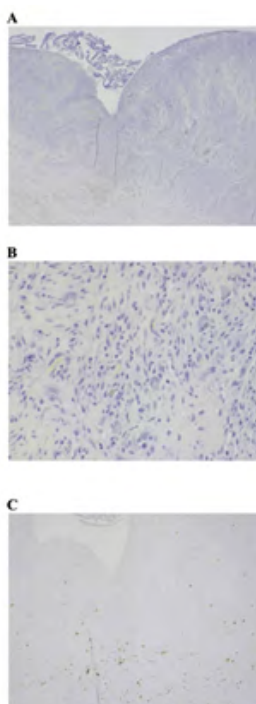


Figure 3: Final pathology revealed mucosal ulceration (a), as well as CMV staining by H&E (b) and immunohistochemistry (c).

4. Discussion

CMV is a DNA virus and typically results in only sub-clinical symptoms to those infected after infancy [5]. In contrast, acute infection in immunocompromised patients can be fatal. In AIDS patients, a CD4 of less than 50 cell/IU correlates with a higher risk of life-threatening complication. The esophagus, stomach, and colon are the most commonly CMV-infected areas of the gastrointestinal tract, whereas infection of the small bowel is uncommon [6, 7]. While rare, CMV is the most common atraumatic cause of small bowel perforation in immunocompromised individuals. CMV enteritis can cause ulceration, perforation and hemorrhage, but to our knowledge, this is the first case of resulting in the perforation of a prior small bowel anastomosis [2, 8]. The pathophysiology of ulceration and subsequent perforation in CMV enteritis is related to the vessels lined by the vascular endothelial cells (VEC) which are the primary cells targeted by CMV. Although CMV has the capacity to affect many cells in the GI tract, infected VECs become swollen and dysfunctional, resulting in vascular compromise, thrombosis and tissue hypoxia [9]. Subsequent ischemia and necrosis results in perforation, peritonitis, sepsis and death. When suspected, the diagnosis of CMV can be confirmed with upper and lower endoscopy, as well as cross sectional imaging. Common findings on CT include intestinal wall thickening, luminal narrowing, and fistula formation [10]. The diagnosis can be confirmed by a combination of CMV serologic testing and demonstration of inclusion bodies on biopsy and surgical specimens [11]. Gratefully, anti-viral medications have excellent efficacy against CMV when a timely diagnosis is made [12]. Our patient was unique in that his perforation occurred at a prior small bowel anastomosis. In newly formed intestinal anastomoses, factors associated with dehiscence and subsequent perforation include technical error, excessive tension, and poor blood supply resulting in ischemia and necrosis [13, 14]. Additional factors which may contribute to anastomotic disruption include older patient age, anemia, malnutrition, and weight loss [15, 16]. However, even a technically perfect anastomosis can leak. This patient's anastomosis was decades-old and healed. The healing process involves inflammatory, proliferative, and remodeling phases. Angiogenesis is critical to the healing process, and typically occurs during the proliferative phase and depends on various soluble factors, including vascular endothelial growth factor (VEGF) [17]. During healing, new capillaries form and within days are arranged into a new microvascular network permeating through granulation tissue. Subsequently, the formation of collagen yields a scar with a reduction in the density of vessels supplying the newly-healed wound [17]. In the case of our patient, his healed small bowel anastomosis likely had a poor vascular supply, making this area of the GI tract a particularly susceptible area to ischemia secondary to CMV-mediated enteritis. In summary, CMV enteritis is an important diagnostic consideration in immunocompromised patients presenting with acute abdominal pain. This report presents the first case of a perforation of a prior small bowel anastomosis secondary to CMV-enteritis in

an AIDS patient. Although uncommon, CMV enteritis can affect the small bowel and result in life threatening hemorrhage and perforation, especially in immunocompromised patients with prior GI surgery. Treatment for gastrointestinal CMV disease includes induction with an antiviral agent – usually ganciclovir – for approximately three to six weeks [12]. Providers should consider intravenous antiviral therapy in patients with severe CMV GI disease, although oral valganciclovir is an acceptable alternative in patients who can tolerate oral medications [18]. Our patient did have one week of prescribed valganciclovir treatment, but was notable for non-compliance in the past and had an Acute Stress Disorder regarding his new diagnosis of AIDS. Perhaps a combination of medication non-compliance and the patient's prior GI surgery made him particularly susceptible to severe CMV enteritis and perforation. When an AIDS patient presents with acute abdominal pain, a high index of suspicion for CMV enteritis is important – followed by timely antiviral treatment to prevent life-threatening complications.

References

1. Karigane D, Takaya S, Seki Y. Cytomegalovirus enteritis in immunocompetent subjects: a case report and review of the literature. *J Infect Chemother.* 2014; 20(5): 325-9.
2. Bang S, Park YB, Kang BS. CMV enteritis causing ileal perforation in underlying lupus enteritis. *Clin Rheumatol.* 2004; 23(1): 69-72.
3. Naseem Z, Hendahewa R, Mustaev M. Cytomegalovirus enteritis with ischemia in an immunocompetent patient: A rare case report. *Int J Surg Case Rep.* 2015; 15: 146-8.
4. Morunglav M, Theate I, Bertin G. CMV enteritis causing massive intestinal hemorrhage in an elderly patient. *Case Rep Med.* 2010; 2010.
5. Arnar DO, Gudmundsson G, Theodors A. Primary cytomegalovirus infection and gastric ulcers in normal host. *Dig Dis Sci.* 1991; 36(1): 108-11.
6. Goodgame RW. Gastrointestinal cytomegalovirus disease. *Ann Intern Med.* 1993; 119(9): 924-35.
7. Chamberlain RS, Atkins S, Saini N. Ileal perforation caused by cytomegalovirus infection in a critically ill adult. *J Clin Gastroenterol.* 2000; 30(4): 432-5.
8. Taniwaki S, Kataoka M, Tanaka H. Multiple ulcers of the ileum due to Cytomegalovirus infection in a patient who showed no evidence of an immunocompromised state. *J Gastroenterol.* 1997; 32(4): 548-52.
9. Golden MP, Hammer SM, Wanke CA. Cytomegalovirus vasculitis. Case reports and review of the literature. *Medicine (Baltimore).* 1994; 73(5): 246-55.
10. Machens A, Bloechle C, Achilles EG. Toxic megacolon caused by cytomegalovirus colitis in a multiply injured patient. *J Trauma.* 1996; 40(4): 644-6.
11. Azer SA, Limaie F. Cytomegalovirus Colitis. *StatPearls. Treasure Island (FL).* 2022.
12. Blanshard C, Benhamou Y, Dohin E. Treatment of AIDS-associated gastrointestinal cytomegalovirus infection with foscarnet and ganciclovir: a randomized comparison. *J Infect Dis.* 1995; 172(3): 622-8.

13. Nasirkhan MU, Abir F, Longo W. Anastomotic disruption after large bowel resection. *World J Gastroenterol.* 2006; 12(16): 2497-504.
14. Khoury GA, Waxman BP. Large bowel anastomoses. I. The healing process and sutured anastomoses. A review. *Br J Surg.* 1983; 70(2): 61-3.
15. Sciuto A, Merola G, De Palma GD. Predictive factors for anastomotic leakage after laparoscopic colorectal surgery. *World J Gastroenterol.* 2018; 24(21): 2247-60.
16. Makela JT, Kiviniemi H, Laitinen S. Risk factors for anastomotic leakage after left-sided colorectal resection with rectal anastomosis. *Dis Colon Rectum.* 2003; 46(5): 653-60.
17. Tonnesen MG, Feng X, Clark RA. Angiogenesis in wound healing. *J Investig Dermatol Symp Proc.* 2000; 5(1): 40-6.
18. Kaplan JE, Benson C, Holmes KK. Guidelines for prevention and treatment of opportunistic infections in HIV-infected adults and adolescents: recommendations from CDC, the National Institutes of Health, and the HIV Medicine Association of the Infectious Diseases Society of America. *MMWR Recomm Rep.* 2009; 58(RR-4): 1-207; quiz CE1-4.