

## Renal Involvement in Inflammatory Bowel Disease: A Two-Center Retrospective Study

Najla Zran<sup>1,2</sup>, Soumaya Chargui<sup>1,2</sup>, Sahar Agrebi<sup>1,2</sup>, Nada Sellami<sup>1,2</sup>, Hayet Kaaroud<sup>1,2</sup>, Ezzedine Abderrahim<sup>1,2</sup>, Awatef Azzabi<sup>1</sup>, Yosra Guedri<sup>1</sup>, Sanda Mrabet<sup>1</sup> and Dorsaf Zellama<sup>3</sup>

<sup>1</sup>Department of Nephrology, Charles Nicolle Hospital, Tunis, Tunisia

<sup>2</sup>Laboratory of Nephropathology (LR00SP01), Tunis, Tunisia

<sup>3</sup>Department of Nephrology, Sahloul Hospital, Sousse, Tunisia

### \*Corresponding author:

Najla Zran,  
Department of Nephrology, Charles Nicolle Hospital,  
Tunis, Tunisia and Laboratory of Nephropathology  
(LR00SP01), Tunis, Tunisia

Received: 03 Dec 2025

Accepted: 23 Dec 2025

Published: 06 Jan 2026

J Short Name: JJGH

### Copyright:

©2026 Najla Zran, This is an open access article distributed under the terms of the Creative Commons Attribution License, which permits unrestricted use, distribution, and build upon your work non-commercially

### Keywords:

Crohn's Disease; Ulcerative Colitis; Kidney Diseases; Amyloidosis; Renal Involvement

### Citation:

Najla Zran, Renal Involvement in Inflammatory Bowel Disease: A Two-Center Retrospective Study Japanese Jour of Gastro and Hepatology® 2026; V11(1): 1-6

## 1. Abstract

### 1.1. Introduction and Background

Renal involvement represents a rare but serious complication of inflammatory bowel diseases (IBD).

### 1.2. Methods

We conducted a retrospective descriptive study including patients with IBD and renal involvement followed in two centres.

### 1.3. Results

A total of 40 patients were included, comprising 31 patients with Crohn's disease and nine with ulcerative colitis. The mean age was  $46.6 \pm 16.7$  years, with a male predominance. Renal involvement occurred significantly earlier in patients with Crohn's disease than in those with ulcerative colitis (3 vs. 12 years,  $p = 0.04$ ). The circumstances of diagnosis were mainly proteinuria (45%) and renal failure (40%). Nephrotic syndrome was present in 45% of cases, with a median serum creatinine level of  $158 \mu\text{mol/L}$  [39–1207  $\mu\text{mol/L}$ ]. The renal lesions were heterogeneous: Acute kidney injury was observed in eight patients (20%), while chronic kidney disease was present in 36 cases (90%). Histopathological examination revealed renal amyloidosis (42.5%), followed by IgA nephropathy (5%) and membranous glomerulonephritis (2.5%). Chronic tubulointerstitial nephropathy was reported in 22.5% of patients and nephrolithiasis in 20%. Among our patients, 10% required dialysis at presentation, and 35% progressed to this stage after a median delay of 30 months [2–204]. An estimated glomerular filtration rate (eGFR)  $<60 \text{ mL/min/1.73 m}^2$  at presentation was the only risk factor for progression to end-stage kidney disease, with an odds ratio (OR) of 6.12.

### 1.4. Conclusion

Renal involvement associated with IBD is heterogeneous and may progress to dialysis. Our findings highlight the crucial importance of early diagnosis and multidisciplinary management of this condition.

## 2. Introduction

Chronic inflammatory bowel diseases (IBD) mainly include Crohn's disease (CD) and ulcerative colitis (UC). They are characterized by chronic inflammation of the digestive tract that occurs in flare-ups, resulting from a dysregulation of the immune response to environmental and genetic factors. The diagnosis is based on a combination of clinical, biological, radiological, endoscopic, and histological findings [1,2].

In addition to digestive symptoms, IBD is frequently accompanied by extraintestinal manifestations, reported in 6 to 47% of cases, affecting in particular the osteoarticular, cutaneous, ocular, haematological, and hepatobiliary systems [3].

Renal involvement is a recognized extraintestinal manifestation of IBD, with an estimated prevalence of between 4% and 23%. They are highly heterogeneous in clinical, biological, and histopathological terms, and can manifest as urinary lithiasis, tubulointerstitial nephropathy, glomerulonephritis, and renal amyloidosis [4].

There are multiple mechanisms involved: immune-inflammatory phenomena common to intestinal involvement, metabolic complications related to digestive disease, or renal toxicity of certain treatments. Although relatively rare, these complications can compromise the renal and vital prognosis of patients [5].

In this context, we conducted a retrospective descriptive study in

two center, including patients with IBD who were being monitored for kidney damage. The main objective was to analyze the clinical, biological, histological, and evolutionary characteristics of the various types of kidney damage observed in IBD.

### 3. Methods and Materials

#### 3.1. Study Design and Population

This was a retrospective two-centre. Patients with a confirmed diagnosis of IBD who were followed or hospitalized during the study period, and presented with renal involvement. Renal involvement was defined by the presence of an abnormal urinary sediment and/or an alteration of renal function. Patients with an unconfirmed diagnosis of IBD or incomplete medical records were excluded.

#### 3.2. Data Collection

Collected data included demographic characteristics, IBD features, treatments, renal manifestations, biological findings, histological results when available, and outcomes.

#### 3.3. Statistical Analysis

Quantitative variables were expressed as mean  $\pm$  standard deviation or median with range. Qualitative variables were expressed as frequencies and percentages. Comparisons were performed using Student's t-test or the Mann-Whitney test for continuous variables and the chi-square or Fisher's exact test for categorical variables.

Factors associated with progression to end-stage kidney disease were assessed using logistic regression analysis.

## 4. Results

### 4.1 Baseline Characteristics of the Study population

We collected data from 40 patients, of whom 27 (67.5%) were followed in the first center and 13 (32.5%) in the second centre. Among these patients, 31 (77.5%) had CD and nine (22.5%) had UC (Table 1). The mean age was  $46.6 \pm 16.7$  years, with a male predominance (57.5%). The median follow-up duration was 6 years [0–34], significantly longer in UC than in CD (12 vs. 3 years,  $p = 0.04$ ). While renal manifestation revealed IBD in three cases (7.5%), including two cases of CD and one case of UC. The extra-intestinal manifestations in patients with CD and UC are shown in Table 1. Anemia was the most common manifestation, with a prevalence of 80.6%. Among the 31 patients with CD, ileocolonic disease was the most frequent (57.1%), nine (29%) had anoperineal manifestations.

As treatment, systemic steroids and 5-ASA were primarily used, in addition to immunomodulating and anti-TNF agents. There was a trend toward more prescriptions of 5-ASA in patients with UC than with CD ( $P=0.007$ ). Seventeen-point five percent of the patients had undergone IBD-related surgery (total colectomy, small bowel resection).

**Table 1:** Baseline characteristics of patients with IBD and renal involvement.

	IBD n = 40	CD n = 31	UC n = 9	P
Age in years (mean $\pm$ SD)	46.6 $\pm$ 16.7	44.6 $\pm$ 16.8	53.4 $\pm$ 15.4	0.14
Sex ratio M/F	1.35	1.58	0.8	0.45
Tobacco use, n (%)	18 (45)	17 (54.8)	1 (11.1)	0.19
Comorbid diseases, n (%)				
Diabetes mellitus	5 (12.5)	1 (9.7)	2 (22.2)	0.31
Hypertension	7 (17.5)	6 (19.4)	1 (11.1)	0.67
Follow-up period in years, (median [range])	6 [0-34]	3 [0-34]	12 [0-25]	<b>0.04</b>
EIM, n (%)				
Hematologic				
Anemia	32 (80)	25 (80.6)	7 (77.8)	0.58
Thrombocytosis	7 (17.5)	7 (22.5)	0	<b>0.03</b>
Articular				
Arthralgia	8 (20)	6 (19.4)	2 (22.2)	0.81
AS	9 (22.5)	8 (25.8)	1 (11.1)	0.53
Ocular				
Uveitis	6 (15)	4 (12.9)	2 (22.2)	0.49
Treatments, n (%)				
5-ASA	18 (45)	10 (32.2)	8 (88.9)	<b>0.007</b>
Systemic steroids	20 (50)	17 (54.8)	3 (33.3)	0.26
Azathioprine	11 (27.5)	9 (29)	2 (22.2)	0.68
Anti-TNF alpha	4 (10)	4 (12.9)	0	0.33

IBD - Inflammatory bowel disease; CD - Crohn disease; UC - Ulcerative colitis; EIM - Extra-intestinal manifestations; AS - Ankylosing Spondylitis; CRP - C-reactive protein; 5-ASA – 5 aminosalicylic acid; TNF - tumor necrosis factor.

## 4.2 Renal Manifestations in Patients with Inflammatory Bowel Disease

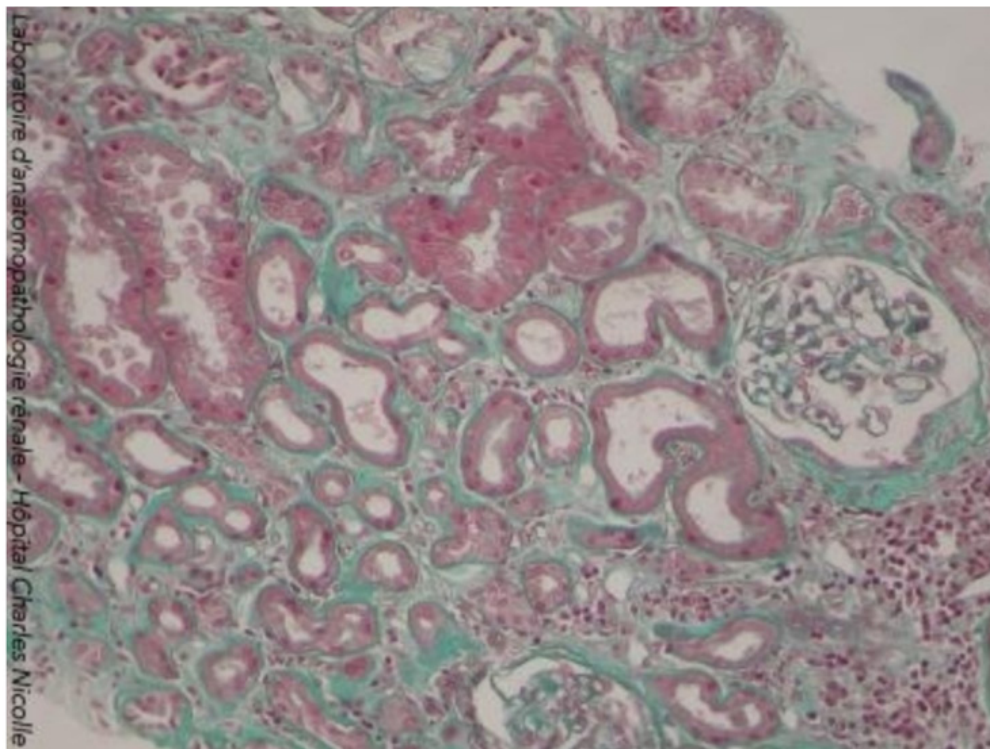
Table 2 summarizes the renal manifestations, with individual patients potentially presenting multiple types of involvement. The circumstances leading to the detection of renal involvement were predominantly proteinuria (45%) and kidney failure (40%), followed by haematuria (5%), renal colic (5%), malignant hypertension (2.5%), and hypokalemia (2.5%). On examination, proteinuria, present in nearly 80% of patients in both groups, was the most common urinary finding, the median proteinuria was 3.12 g/24 h [range: 0–20.7]. Chronic kidney disease (CKD) was present in 90%, an estimated glomerular filtration rate (eGFR) <60 mL/min/1.73 m<sup>2</sup>, corresponding to CKD stage 3a to 5, was present in 58.4% of patients in our study. Acute kidney injury (AKI) was reported in 8 cases (20%). The etiologist included prerenal causes in six patients due to dehydration, acute interstitial nephritis secondary to 5-ASA

in one patient, and acute tubular necrosis in one patient. Renal biopsy was performed in twelve patients (30%), most frequently for nephrotic syndrome (8 patients), followed by renal insufficiency (2 patients), and proteinuria or hematuria (1 patient each). AA amyloidosis was the most histological finding in our series, observed in 17 patients (42.5%). The median time between the diagnosis of IBD and the discovery of renal amyloidosis was 36 months. The diagnosis was confirmed by labial salivary gland biopsy in 10 cases and by renal biopsy in seven cases. Two patients with CD who had undergone renal biopsy due to proteinuria and hematuria were diagnosed with IgA nephropathy. One patient with UC underwent a renal biopsy after presenting with a pure nephrotic syndrome, and histopathological examination revealed a membranous nephropathy. Nine patients had chronic tubulointerstitial nephritis, among these patients, three had been treated with 5-ASA (Figure 1). Renal lithiasis was identified in eight patients (20%). The median time to stone formation was 36 months [range: 2–204 months].

**Table 2:** Renal manifestations in patients with inflammatory bowel disease.

	IBD n = 40	CD n = 31	UC n = 9	P
<b>Urinary findings, n (%)</b>				
Proteinuria	33 (82.5)	26 (83.9)	7 (77.8)	0.67
Hematuria	11 (27.5)	9 (29)	2 (22.2)	0.82
<b>Laboratory parameters</b>				
Creatinine (μmol/L), median [range]	186 [39 - 1207]	127 [39 - 1207]	280 [52 - 759]	0,44
GFR (mL/min/1.73 m <sup>2</sup> ), median [range]	33,7 [4.4 – 247,1]	49,2 [4,4 – 247,1]	18,5 [6,4 - 105,2]	0,42
Nephrotic syndrome, n (%)	18 (45%)	14 (45.1)	4 (44.4)	0.97
<b>Clinical entities, n (%)</b>				
Acute kidney injury	8 (20)	5 (16.1)	3 (33.3)	0.34
Chronic kidney disease	36 (90)	29 (93.5)	7 (77.8)	0.38
<b>Pathological findings, n (%)</b>				
AA amyloidosis	17 (42.5)	14 (45.1)	3 (33.3)	0.52
IgA nephropathy	2 (5)	2 (6.4)	0	-
Membranous nephropathy	1 (2.5)	0	1 (11.1)	-
Indeterminate Glomerular Nephropathies	2 (5)	2 (6.4)	0	-
Tubulointerstitial Nephritis	9 (22.5)	7 (22.5)	2 (22.2)	0.98
Renal calculi	8 (20)	7 (22.5)	1 (22.2)	0.65

IBD - Inflammatory bowel disease; CD - Crohn disease; UC - Ulcerative colitis.



**Figure 1:** Among our patients, 10% were on dialysis at initial presentation, and 35% progressed to dialysis within a median time of 30 months (range: 2–204), including 10 patients with CD and four with UC ( $p=0.97$ ). The median time to end-stage kidney disease (ESKD) was 36 months [range: 4–204] in CD and 13 months [range: 2–96] in UC ( $p=0.65$ ). In patients with AA amyloidosis, the median GFR declined from 57.44 to 16.49 mL/min/1.73 m<sup>2</sup> over one year of follow-up. One patient was already at ESKD at baseline, while eight others progressed to ESKD after a median of 19 months. Among patients with chronic tubulointerstitial nephritis, two were already on dialysis at baseline, and five additional patients reached this stage after a median of 36 months. No significant differences were observed according to the type of renal involvement ( $p=0.89$ ). GFR <60 mL/min/1.73 m<sup>2</sup> at presentation was the only risk factor for progression to ESKD, with an OR of 6.12.

## 5. Discussion

This study provides a detailed analysis of the spectrum of renal manifestations observed in patients with IBD. Renal involvement occurred significantly earlier in CD than in UC, likely reflecting a higher inflammatory burden and more aggressive disease course in CD. Renal disease preceded the diagnosis of IBD in 7.5% of cases. The timing of renal involvement varies across studies: some report an association with longer disease duration [6,7], while others describe renal manifestations occurring concomitantly with or even prior to the diagnosis of IBD (8) [9]. In our cohort, ileocolonic disease was the most frequent CD phenotype. Perianal disease was present in 29% of CD patients, a higher proportion than reported in population-based studies around 20% [10], likely reflecting its association with more severe and complicated disease forms [11,12]. The circumstances leading to the detection of renal involvement were predominantly proteinuria (45%) and kidney failure (40%). In the literature, urinary sediment abnormalities such as hematuria and proteinuria are reported as the most common presenting symptoms [13,14]. Renal insufficiency was documented in 8.6% of cases in the study by A. Fayed et al. [15] and in 10% of cases in the series by Yang et al. [16]. In our study, we observed that kidney failure was reported more frequently than in previously published data. This discrepancy may be attributable to our study being conducted in a nephrology hospital setting, as well as to the delayed referral of patients to nephrologists.

AKI was identified in 20% of patients, most often prerenal and secondary to dehydration during inflammatory flares. This aligns with published data identifying hypovolemia as the main mechanism of AKI in IBD, generally reversible once the underlying trigger is corrected [17].

AA amyloidosis was the most frequent renal manifestation in our cohort (42.5%), predominantly affecting patients with CD. This finding is consistent with studies reporting a higher prevalence of AA amyloidosis in CD than in UC [18]. The median duration of IBD was 36 months (range: 0–300), and IBD was revealed by amyloidosis in two cases. Tosca et al. reported that amyloidosis typically occurs in long-standing IBD, with an average interval of 14 years between the two diagnoses [18]. However, concomitant discovery of IBD and amyloidosis is not uncommon; in a 25-year study including 500 IBD patients, 18 had AA amyloidosis, five of whom were diagnosed at the same time as their IBD [19]. Amyloidosis was frequently associated with severe or complicated IBD phenotypes, including pelvic abscesses, fistulas, and extraintestinal manifestations particularly joint involvement [18,20].

Glomerular diseases were less frequently reported in our study, primarily due to the limited number of renal biopsies. In contrast, the literature shows that glomerular diseases account for a significant proportion of renal involvement in IBD. Renal biopsy remains essential for their diagnosis, revealing various histopathological patterns, including minimal change disease, focal segmental



glomerulosclerosis, membranous nephropathy, IgA nephropathy, membranoproliferative glomerulonephritis, C3 glomerulopathy, and crescentic glomerulonephritis. Although the underlying mechanisms are not fully elucidated, most studies suggest a close relationship between intestinal inflammatory activity and glomerular injury, with renal improvement often observed following IBD remission [8,21,22].

Tubulointerstitial lesions were also frequent and could represent either extraintestinal manifestations of IBD or drug-induced injuries, particularly from 5-ASA. In the series by Ambruzs et al. [21], acute and chronic interstitial nephritis accounted for 19% of renal biopsies, making them the second most common lesion after IgA nephropathy [23]. 5-ASA-related nephrotoxicity, though rare (<0.5%), typically presents as interstitial nephritis and is likely mediated through delayed hypersensitivity mechanisms [24]. Additional IBD-related factors including enteric hyperoxaluria, amyloidosis, hypokalemia, and recurrent urinary infections may also contribute to tubulointerstitial injury [21]. Nephrolithiasis was identified in 20% of patients, predominantly those with CD. The lithogenic risk in IBD is higher than in the general population, driven largely by enteric hyperoxaluria, alterations in the gut microbiota, decreased urinary inhibitors of stone formation, and chronic dehydration leading to uric acid stones [25]. The median time to stone formation (36 months) aligns with reported intervals of 4 to 7 years after IBD diagnosis [26]. Nearly half of the patients progressed to ESKD, a proportion higher than that reported in population-based studies. This likely reflects referral bias and advanced renal disease at presentation. The particularly rapid decline in renal function seen in patients with AA amyloidosis, who represented the majority in our study, aligns with findings from, who described an accelerated progression to ESKD in IBD-associated AA amyloidosis [27,28]. Chronic kidney failure at diagnosis emerged as the only independent predictor of progression to end-stage kidney disease, underscoring the importance of early detection and timely management.

## 6. Conclusion

In view of these results and the available literature, renal involvement in IBD is heterogeneous and may progress to ESKD. Early detection through routine evaluation of urinary sediment and vigilant monitoring of kidney function is therefore imperative. A structured follow-up and multidisciplinary management approach are essential to stabilize and potentially induce remission of the underlying renal pathology.

## References

1. Maaser C, Sturm A, Vavricka SR, Kucharzik T, Fiorino G. ECCO-ESGAR guideline for diagnostic assessment in IBD part 1: initial diagnosis, monitoring of known IBD, detection of complications. *J Crohns Colitis*. 2019; 13(2): 144-164.
2. Amiot A, Viennot S, Uzzan M, Rivière P, Le Cosquer G. Practice guidelines for the diagnosis and management of ulcerative colitis (short version). *Hepato-Gastro & Oncologie Digestive*. 2022; 29(3): 297-333.
3. Vavricka SR, Schoepfer A, Scharl M, Lakatos PL, Navarini A, Rogler G. Extraintestinal manifestations of inflammatory bowel disease. *Inflamm Bowel Dis*. 2015; 21(8): 1982-1992.
4. Alex G, Skamnelos R, Giagkou E, Malakos Z, Katsanos KH, Christodoulou DK. Inflammatory bowel diseases accompanied by renal impairment. *J Clin Exp Nephrol*. 2015; 1(1).
5. Mutalib M. Renal involvement in paediatric inflammatory bowel disease. *Pediatr Nephrol*. 2021; 36(2): 279-285.
6. Primas C, Novacek G, Schweiger K, Mayer A, Eser A. Renal insufficiency in IBD prevalence and possible pathogenetic aspects. *J Crohns Colitis*. 2013; 7(12): e630-e634.
7. Katsanos K, Tsianos EV. The kidneys in inflammatory bowel disease. *Ann Gastroenterol*. 2002; 15(1): 41-52.
8. Corica D, Romano C. Renal involvement in inflammatory bowel diseases. *J Crohns Colitis*. 2016; 10(2): 226-235.
9. Pardi DS, Tremaine WJ, Sandborn WJ, McCarthy JT. Renal and urologic complications of inflammatory bowel disease. *Am J Gastroenterol*. 1998; 93(4): 504-514.
10. Tsai L, McCurdy JD, Ma C, Jairath V, Singh S. Epidemiology and natural history of perianal Crohn's disease: a systematic review and meta-analysis of population-based cohorts. *Inflamm Bowel Dis*. 2022; 28(10): 1477-1484.
11. Beaugerie L, Seksik P, Nion-Larmurier I, Gendre JP, Cosnes J. Predictors of Crohn's disease. *Gastroenterology*. 2006; 130(3): 650-656.
12. Rankin GB, Watts HD, Melnyk CS, Kelley ML. National Cooperative Crohn's Disease Study: extraintestinal manifestations and perianal complications. *Gastroenterology*. 1979; 77(4): 914-920.
13. Dincer MT, Dincer ZT, Bakkaloglu OK, Yalin SF, Trabulus. Renal manifestations in inflammatory bowel disease: a cohort study during the biologic era. *Med Sci Monit*. 2022; 28: e936497.
14. Jang HM, Baek HS, Kim JE, Kim JY, Lee YH. Renal involvement in children and adolescents with inflammatory bowel disease. *Korean J Pediatr*. 2018; 61(10): 327-331.
15. Abdel-Aziz M, Fayed A. Patterns of renal involvement in a cohort of patients with inflammatory bowel disease in Egypt. *Acta Gastro-Enterol Belg*. 2018; 81: 381-385.
16. Yang Z, Xu X, Dong Y, Zhang Y. The pathological and outcome characteristics of renal lesions in Crohn's disease. *BMC Nephrol*. 2022; 23(1): 256.
17. Lewis B, Mukewar S, Lopez R, Brzezinski A, Hall P, Shen B. Frequency and risk factors of renal insufficiency in inflammatory bowel disease inpatients. *Inflamm Bowel Dis*. 2013; 19(9): 1846-1851.
18. Tosca Cuquerella J, Bosca-Watts MM, Anton Ausejo R, Tejedor Alonso S, Mora De Miguel F, Mínguez Perez M. Amyloidosis in inflammatory bowel disease: a systematic review of epidemiology, clinical features, and treatment. *J Crohns Colitis*. 2016; 10(10): 1245-1253.
19. Wester AL, Vatn MH, Fausa O. Secondary amyloidosis in inflammatory bowel disease: a study of 18 patients admitted to Rikshospitalet University Hospital, Oslo, from 1962 to 1998. *Inflamm Bowel Dis*. 2001; 7(4): 295-300.
20. Greenstein AJ, Sachar DB, Nannan Panday AK, Dikman SH, Meyers S. Amyloidosis and inflammatory bowel disease: a 50-year experience with 25 patients. *Medicine (Baltimore)*. 1992; 71(5): 261-270.

21. Ambruzs JM, Larsen CP. Renal manifestations of inflammatory bowel disease. *Rheum Dis Clin North Am.* 2018; 44(4): 699-714.
22. Oikonomou K, Kapsoritakis A, Eleftheriadis T, Stefanidis I, Potamianos S. Renal manifestations and complications of inflammatory bowel disease. *Inflamm Bowel Dis.* 2011; 17(4): 1034-1045.
23. Ambruzs JM, Walker PD, Larsen CP. The histopathologic spectrum of kidney biopsies in patients with inflammatory bowel disease. *Clin J Am Soc Nephrol.* 2014; 9(2): 265-270.
24. Gisbert JP, González-Lama Y, Maté J. 5-Aminosalicylates and renal function in inflammatory bowel disease: a systematic review. *Inflamm Bowel Dis.* 2007; 13(5): 629-638.
25. Gkentzis A, Kimuli M, Cartledge J, Traxer O, Biyani CS. Urolithiasis in inflammatory bowel disease and bariatric surgery. *World J Nephrol.* 2016; 5(6): 538-546.
26. Gaspar SR da S, Mendonça T, Oliveira P, Oliveira T, Dias J, Lopes T. Urolithiasis and Crohn's disease. *Urol Ann.* 2016; 8(3): 297-304.
27. Sharma P, Aguilar R, Siddiqui OA, Nader MA. Secondary systemic amyloidosis in inflammatory bowel disease: a nationwide analysis. *Ann Gastroenterol.* 2017; 30(5): 504-511.
28. Sattianayagam PT, Gillmore JD, Pinney JH, Gibbs SDJ, Wechalekar AD. Inflammatory bowel disease and systemic AA amyloidosis. *Dig Dis Sci.* 2013; 58(6): 1689-1697.